Horizon 2020

Project title: AuTonomous intraLuminAl Surgery

System specifications for targeted intraluminal interventions

Deliverable number: D10.2

Version 2.0.0

Funded by the European Union's Horizon 2020 research and innovation programme under the Marie Sklodowska-Curie Grant Agreement No. 813782

Project Acronym: ATLAS

Project Full Title: AuTonomous intraLuminAl Surgery

Call: H2020-MSCA-ITN-2018

Grant Number: 813782

Project URL: https://atlas-itn.eu

Deliverable nature:	Report (R)
Dissemination level:	Public (PU)
Contractual Delivery Date:	March 31, 2020
Actual Delivery Date	April 19, 2020
Number of pages:	23
Keywords:	System specification, Colonoscopy, Ureteroscopy. Endovascular Catheterization
Authors:	Gianni Borghesan, KU Leuven Fabian Trauzettel, TU Delft & KU Leuven Mohammad Hasan Dad Ansari, SSSA & KU Leuven Beatriz Farola Barata, KU Leuven & UNIVR Di Wu, KU Leuven & TU Delft Zhen Li, POLIMI & TU Delft Jorge Lazo, POLIMI & UNISTRA Martina Finocchiaro, UPC & SSSA Thao Hà Xuan, KU Leuven & SSSA Chun-Feng Lai, TU Delft & POLIMI Sanat Ramesh, UNIVR & UNISTRA Sujit Kumar Sahu, SSSA & UNISTRA Luca Sestini, UNISTRA & POLIMI Guiqiu Liao, UNISTRA & UNIVR Ameya Pore, UNIVR & UPC Fernando Gonzalez Herrera, UNISTRA & KU Leuven
Peer review:	Gianni Borghesan, KU Leuven Alicia Casals, UPC Arianna Menciassi, SSSA Emmanuel Vander Poorten, KU Leuven

Abstract

This deliverable summarizes the first efforts from the ESRs in designing common demonstrator platforms for developing and testing autonomous intraluminal navigation schemes. Through this endeavour ESRs are encouraged to work accross institutional borders towards a common application target. Thanks to this joint effort ESRs learn to explain their work to peers and are offered the opportunity to learn related technologies in a similar hands-on fashion.

The deliverable is the result of these first collaborative efforts. The work is the outcome of the first integration meeting that took place in Leuven, the 22nd of January 2020. The effort in integration will be followed-up during the whole duration of the project and will be reported in subsequent Deliverables 5.2, 5.3, and 5.4. The purpose is that at the end of the project three intraluminal navigation systems initiated here, can be demonstrated to the broader public.

The report starts by identifying and describing a specific use case within each of the broader medical scenarios: Colonoscopy and Gastroscopy (C1), Ureteroscopy (C2), and Endovascular Catheterization (C3). The ATLAS deliverable 'D10.1 Surgical Workflow of Intraluminal Interventions' formed the base for this selection and the derived description. Then, a vision on an autonomous intraluminal navigation scenario is elaborated and the specifications for the corresponding autonomous intraluminal systems are sketched.

All ESRs contributed to this deliverable. The ESRs were asked to work in group to detail their scenario with the greatest care. In a second step each team was asked to critically evaluate the contributions from the other scenarios. Finally, the ESRs received the comments from the other teams and were asked to incorporate the requests for changes or provide additional explanation. By mimicking a typical paper review process ESRs experienced both sides of the publication process. It goes without say that this approach also contributed to the overall quality of the deliverable.

Contents

List of Figures

List of Tables

List of Acronyms

2D Two Dimensional
3D Three Dimensional
CT Computed Tomography
CTO Chronic Total Occlusion
EM Electro-Magnetic
EFTR Endoscopic Full Thickness Resection
EPMR Endoscopic Piecemeal Mucosal Resection
ESD Endoscopic Submucosal Dissection
FMEA Failure Mode and Effects Analysis
FBG Fiber Bragg Grating
ESR Early Stage Researcher
LST Laterally Spreading Tumor
GUI Graphical User Interface
NTA Network-wide Training Activity
HMI Human-Machine graphical user-Interface
IVUS intravascular ultrasound
NOTES Natural Orifice Transluminal Endoscopic Surgery
OCT Optical Coherence Tomography
OR Operating Room
PCI Percutaneous coronary intervention
PET Positron Emission Tomography
SPECT Single-Photon Emission Computerized Tomography
UAS ureteral access sheath

1 Introduction

Integration is a cornerstone of the *ATLAS* project. *ATLAS* will build up devices that are able to perform autonomous intraluminal navigation. In order for realizing such complex behaviour different technological components need to be developed, each with a specific functionality. Nevertheless to accomplish autonomous navigation all of these components need to work together, be able to communicate and exchange information. In short a seemless integration of components is a must.

In addition, for these systems to be useful, they should be designed while maximally taking into account the constraints imposed by the targeted application. Typically this information needs to be obtained from the expert surgeons or from interacting with that expert surgeon. Moreover, while not the earliest concern in this project, the development of such sophisticated system should conform to medical directives and regulatory guidelines. At present, surgical systems with high levels of autonomy are particularly challenging many regulatory issues still need to be tackled [33]. A systematic approach is thus needed.

Another constraint that has to be taken into account during the process of developing a surgical system is that the process itself needs to be documented in detail: as a robotic device for assisted surgery is considered a medical device, it must conform to all the regulations described in the medical device directive, [7]: this implies the complete traceability of materials and revisions of each aspect of the system, thus bringing to a structured and certifiable design and development process.

While *ATLAS* does not plan to translate the developed prototypes to human trials, we do wish to take some key aspects in this regard into account.

1.1 System Specification

In this section, we will describe the general process in deriving a system specification. This information was presented to the ESRs who took this into account during their interactions and investigations.

The very first step in the design process is to acquire the knowledge of the surgical procedure, in particular the understanding of the surgical work-flow, that allows to better understand **the user needs**. A description of the surgical work-flow, namely the contents of deliverable D10.1 - *Surgical work-flow of intraluminal interventions* was made available to the ESRs. Note that these topics will be further discussed in the Network-wide Training Activity (NTA) that will be organised by the University of Strasbourg.

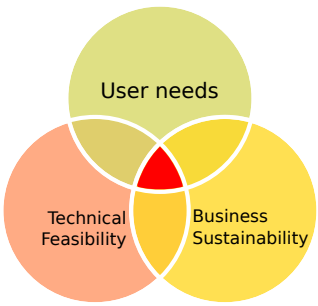

Figure 1.1: Development is profitable only when all the constraints are met.

In addition to the user needs, two other aspects must be addressed if one wants to make a viable technological tool, namely: the **technical feasibility** should be addressed. This includes the problem of realising a system in such a way that its robustness and safety can be guaranteed, and the **business sustainability**. This aspect considers the anticipated profitability of the technology under study. This entails an understanding of the potential use cases and the added value for patients and for the broader healthcare system. These three requirements are graphically depicted in Figure 1.1.

During the **system specification** a number of points need to considered and these aspects should be described as well. In the following a summary of the main topics that need to covered are listed.

Clinical Problem At first, it is necessary to have a proper view and understanding of the clinical scenario. This knowledge is necessary in order to understand where the most critical issues lie. This information can tell where is it possible or most opportune to automate tasks. For example tasks that are easy but very common, repetitive and considered overhead are good candidates for automation. This phase also provides insight in the potential impact (*e.g.* in terms of number of treatments) of a specific procedure, and how much benefits it could bring to the procedure or compared to prior state-of-the-art.

Intended use A device should target a very specific set of operations/manoeuvres within the targeted surgical scenario. Determining this scope precisely is essential as a subsequent certification procedure would be pursued for this specific use of the device. Risk assessment would also focus on these parts. Generic uses needs to be contextualised, and so the intended use of the medical device should be clearly stated.

Specification of the application — Use Case This first set of specifications should describe the constraints that are to be adhered to in order to develop a device that meet goal(s) described in *the intended use*. Typical specifications can follow from a desire to avoid deviation from the conventional work-flow of the medical procedure, keep similar instruments size, compatibility with other surgical tools, *etc.*.

General requirements This section addresses the key features that the system will provide, and how these impact in the medical practice of that specific operation.

Functional & Performance requirements Here, the overall requirements are described. Via a top-down decomposition, the general requirements must be contextualised in terms of functional and performance requirements. Requirements must be expressed as much as possible in a quantitative way, rather than in a qualitative way.

Usability requirements Usability requirements are of utmost importance, because they deal with both the quality of the interface of the device, and the amount of time and effort that is needed for a surgeon to reach the level of confidence necessary to employ such device in a real Operating Room (OR). Poor usability greatly deteriorates the appreciation by the user, and will hinder the acceptance of the device by experts. Parameters that affect the usability include the time to set-up, the type of visualization (2D, 3D, head-mounted displays, ...) the main interface (visual, joystick, teloperation, haptic feedback, ...), and the provided assistive technologies.

1.2 Overview of the design and development process of a Medical Device

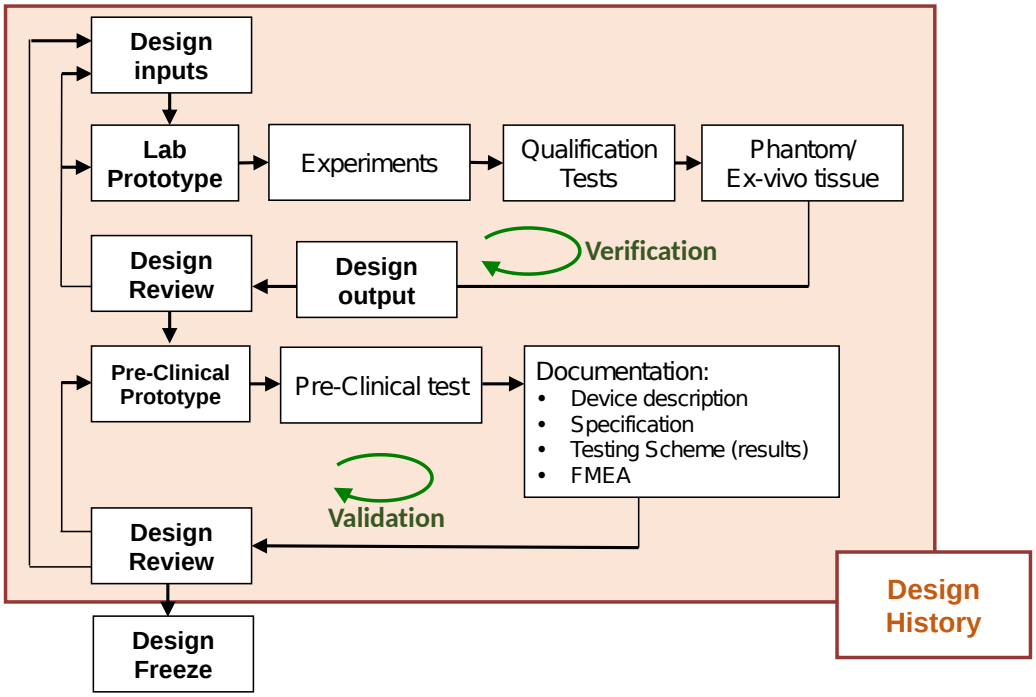

Figure 1.2: Design phases in the realization of a medical device.

Once a specific use case is chosen along with a possible approach, and once it is determined that the criteria summarized in Figure 1.1 are met. The development proces can start up. Figure 1.2 identifies the different steps in a typical development process. After a detailed design and after the development of some first prototypes, the development process moves further

to **verification** and **validation** phases. This is an iterative process so feedback from these phases can be used to re-initiate a next design cycle.

Verification: In the verification phase, a lab prototype or individual components are tested. Experiments are conducted to verify whether the developed components or prototype perform in accordance to the requirements that were initially imposed. These experiments help gathering support material or evidence that can be supplied e.g. when applying for ethical approvals for pre-clinical tests. The verification steps may lead to iterations of the design process. This design is iterated at two levels: if the evaluation of test and experiments highlight a minor issue, the design is updated considering the same design inputs. If the design shows that the initial requirements are not satisfiable, the design should be re-thought. This may entail starting again to draft a more elaborate/accurate or relevant set of system specifications. At this point researchers may shift the proposed solution (*e.g.* alternative technologies, alternative manufacturing processes, ...), or verify whether some of the constraints can be relaxed, without compromising the conclusions of the system specification. If the design outputs are evaluated as satisfactory, the prototype can be brought to the next phase.

Validation: In the validation phase the prototype is tested with the end-user in the loop. Experiments are set up such as to confirm whether the original assumptions regarding the intended use or usability of the system are sound and valid. So where the verification steps are pure technical, in the validation step the human factors come into play. Different levels of validation can be envisioned up to a level of pre-clinical validation. In this stage a new prototype may be built specifically for this purpose. Pre-clinical tests could be *in-vivo* on animals or on cadavers. Often these type of tests will need ethical approval from the relevant national body. For *in-vivo* studies on humans ethical approval is always needed, furthermore approval from the National Body (such as FAGG in Belgium) may need to be obtained before the Ethical Committee will study the application. In most cases different documents need to be supplied, including:

- a technical file
- a risk assessment must be added. This could e.g. be under the form of an Failure Mode and Effects Analysis (FMEA). Such risk assessments will highlight the potential failure modes of the device, the human factors (*e.g.* accidental unintended uses). The prevalence (occurrence) and severity of the different hazards are indicated. Where risk levels were found not to justify to anticipated benefits a design change is needed. The risk assessment will need to be done again after such design change to verify whether the risk level is reduced to an acceptable level.
- a clinical protocol (this is a clear description on how the experimental campaign is planned and will be executed, how the results will be gathered, interpreted, and evaluated, how data will be managed and privacy ensured.
- and informed consent form.

Again, if achieved results are not satisfactory, the review of design can consists of incremental changes in the pre-clinical prototype, or a complete redefinition of the design inputs; in the latter case, the verification cycle is restarted from the beginning. Once the results are satisfactory, the design is frozen. All the documentation (including the *design history*) will be used to draft the documentation required for approval of the device in medical practice.

1.3 First steps to system integration - identification of the clinical need and first system concepts of *ATLAS*

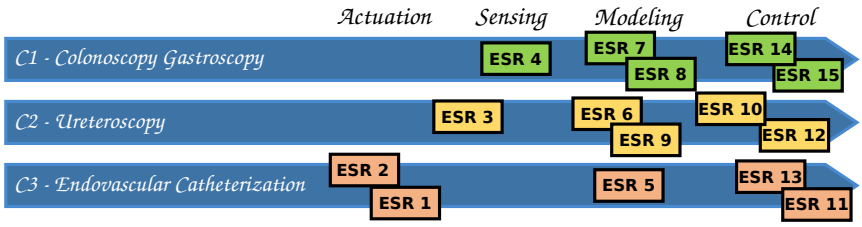

Figure 1.3: Distribution of ESRs in the 3 groups organised such that complementary knowledge can be leveraged maximally.

The ESRs were divided in three groups according to three specific scenarios (1.3). Each group targeted a specific clinical scenario: *Colonoscopy* (**C1**, detailed in Chapter 2), *Uretroscopy* (**C2**, Chapter 3) and *Endovascular catheterization* (**C3**, Chapter 4). Each group had access to the expert advice of one or more of the tutors (PIs to this grant). They provided feedback on the medical scenario and helped identifying the specifications of the integrated system. From this then requirements for such system were drawn.

The composition of groups and tutors is reported in Table 1.1. As shown if Figure 1.3, groups have been created leveraging complementaries between ESRs, in such a way, for each group, at least three of the four following thematic areas are covered: *Actuation*, *Sensing*, *Modeling*, and *Control*.

In group the ESR's had to devise a system that covered most of the targeted outputs of their own anticipated research contributions and that would allow them to produce fully autonomous navigation in the targeted lumen. The next step was to draft up a system specification document for the identified application. Here, the structure depicted in Section 1.1 was followed. The ESRs presented their work to the other groups and the tutors and received feedback which they incorporated in a second round. The different results of these iterations are reported in the next sections.

Table 1.1: Groups composition

C1 – Colonoscopy	C2 – Uretroscopy	C3 – Endovascular Catheterization
ESR 4 — Sujit Sahu	ESR 3 — Thao Hà Xuan	ESR 1 — Fabian Trauzettel
ESR 7 —Guiqiu Liao	ESR 6 — Jorge Lazo	ESR 2 — Mohammad Hasan Dad Ansari
ESR 8 — Luca Sestini	ESR 9 — Sanat Ramesh	ESR 5 — Beatriz Farola Barata
ESR 14 — Fernando Herrera[1]	ESR 10 — Martina Finocchiaro	ESR 11 — Di Wu
ESR 15 — Ameya Pore	ESR 12 — Chun-Feng Lai	ESR 13 — Zhen Li
Tutors		
Benoit Rosa Arianna Menciassi	Elena De Momi Alícia Casals Gelpí	Emmanuel Vander Poorteen

2 C1 – Colonoscopy

Clinical Context

Colonoscopy is a common, safe way to examine the large bowel. It can provide a visual diagnosis of the rectum and colon (mainly cancer screening) and grants the opportunity for biopsy or removal of suspected colorectal cancer lesions. Colorectal cancer ranks third among the most common cancers. Every year in United States almost 150 thousands adults are diagnosed with colon or rectal cancer, and almost 50 thousands deaths are attributed to it, accounting for almost 9% of all cancer deaths [28]. Nearly all colon and rectal cancers begin as polyps, abnormal growths of tissue projecting from colorectal mucosa: about two-thirds of the polyps found during colonoscopies are called "adenomas", and have an estimated 14% probability to develop in cancer in a ten-year span [9]. Therefore it is crucial to detect and remove polyps at an early stage.
During a colonoscopy, doctors who are trained in this procedure (*i.e.* endoscopists) insert a flexible endoscope through the lower digestive tract of the patient, allowing the examination of the rectum and colon. The endoscope is fitted with a miniature camera and a light source which allow the doctor to visualize the colon. Visual data is the primary source of information exploited by the doctor to evaluate the status of the colon. In addition, the doctor can obtain samples of the tissue (biopsies) for diagnosis and eventual tumor staging, and perform surgical procedures, as polypectomies. Other examples of endoscopic surgical procedures are Endoscopic Submucosal Dissection (ESD) [1], used for treating large polyps and superficial cancers in the digestive tract, and Endoscopic Full Thickness Resection (EFTR) [17], used to remove more advanced lesions located in the deeper layers than the submucosa (that have not yet invaded local lymph nodes).
Small polyps (diameter < 10 mm) are effectively resected by means of snare polypectomy (cold or hot, depending on the presence of electrocautery) [15], and collected through the working channel of the endoscope. Large polyps (diameter $>$ 20 mm), are conventionally treated by means of Endoscopic Piecemeal Mucosal Resection (EPMR) in Western countries [16]. The piecemeal approach consists of snaring small pieces of the polyp, and retrieving them through the working channel of the endoscope, as shown in Figure 2.1). A valid alternative to EPMR is represented by ESD, originally pioneered in Japan, where it has already established itself as the optimal and first-line treatment of large Laterally Spreading Tumors (LSTs), supplanting EPMR, with over 15,000 procedures safely and effectively performed every year ([24]). ESD allows "en bloc" resection, as shown in Figure 2.2.

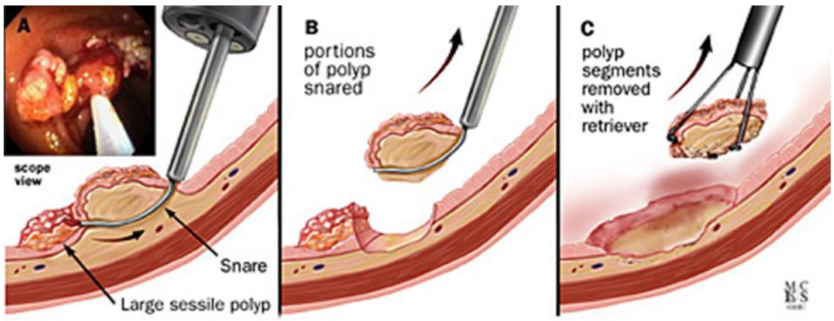

Figure 2.1: Steps of EPMR. The endoscope approaches a large polyp (**A**), snares off a piece of it (**B**) and retrieve it through the working channel (**C**). The procedure is repeated until all the polyp is resected. Image from https://www.semanticscholar.org/paper/Sporadic-(-Nonhereditary-)-Colorectal-Cancer-%3A/34d3d3149bedaedb99a70d67a2c13d6ffccdb1f6

Several works show a local tumor recurrence rate significantly higher with EPMR than with "en bloc" resection via ESD: the local recurrence rate after EPMR has been reported to be up to 50 %, compared with a rate of 0% to 17.8% after "en bloc" resection [27] [25] [26]. Additionally, ESD allows a more accurate histological analysis of the lesion [16]. However, studies point out a marked difference in procedure time, with the mean operating time for ESD versus EPMR being 66.5 vs 29.1 min, and higher perforation rate with ESD (4.9% vs 0.9%) [2]. Despite the well-established long-term advantages

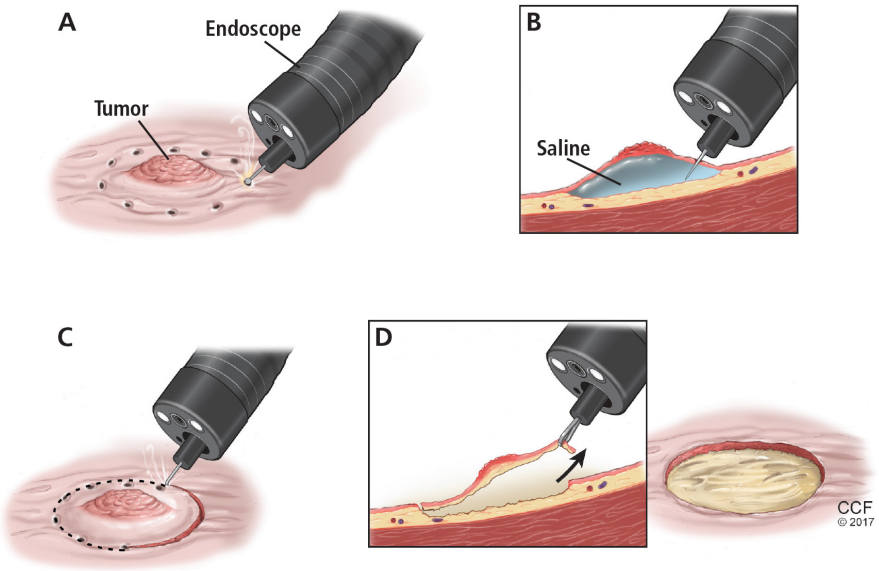

Figure 2.2: Steps of ESD. The endoscope approaches a large polyp and surrounds it with cautery marks (**A**), a saline solution is injected to lift the polyp (**B**), the lifted region is dissected (**C**) and the polyp is retrieved by withdrawing the endoscope outside of the patient (**D**). Image from https://consultqd.clevelandclinic.org/a-minimally-invasive-treatment-for-early-gi-cancers/

in oncological clearance of ESD over EPMR, ESD still fails to achieve acceptable levels of performance in non-Asian countries, due to the technical challenges it involves, combined with a limited availability of ESD expertise and a lower number of ESDs performed in non-Asian countries [11].

Technical Problem

A general technical challenge related to colonoscopy is navigation [5]: short-sighted visualization prevents easy identification of anatomical landmarks and the interaction between the endoscope and colon leads to tissue shifting and deformation, making pre-/intra- operative image registration a complex task. In the presented context of "en bloc" resection, the endoscope has to be withdrawn after each resection to allow the removal of the resected tissue. Generally, multiple polyps are present in the same situ, thus the surgeon has to navigate back to the same location. This consists of two steps:

- Target localization: the location of the current situ should be identified, in order to allow the surgeon to re-reach it after endoscope extraction. Standard endoscopes can only provide visual information from the camera and information about the insertion length: the first is a relative information, which cannot provide the absolute position of the target; the second is often unreliable to localize the target, given the deformability of the colon.
- Navigation and target re-identification: once the endoscope is extracted and reinserted, the surgeon has to navigate back to the situ. This adds to the classical task of endoscopic navigation, the challenge to re-identify the situ.

In order to tackle this problem, this work will focus on the development of a system able to automate the process of target localization and to automatically navigate the endoscope toward the previously identified target.

State of the art in endoscopic navigation

General endoscopic navigation involves the use of different data, falling in three main categories: *preoperative imaging*, *intraoperative imaging*, and *external sensing*.

Preoperative imaging-based navigation involves the use of Computed Tomography (CT) eventually combined with nuclear medicine imaging as Positron Emission Tomography (PET) or Single-Photon Emission Computerized Tomography (SPECT) for functional information. Pre-operative images allow to build a model of the patient, to be registered with intra-operative data. This approach has been applied in the context of Natural Orifice Transluminal Endoscopic Surgery (NOTES) navigation [3]; however, in the colonoscopy context, it presents limitations related to the low contrast of soft tissues in CT images, and to the exposition of patients to ionizing radiation.

Intraoperative imaging allows surgeons to capture real-time views of the organ being operated on, as well as its anatomical surroundings, and enables more precise targeting during procedures. Intraoperative imaging modalities are widely used to examine anatomical structures either on the surface of an organ or beneath it. The main intraoperative imaging techniques are endoscopic imaging, endoscopic ultrasound and Optical Coherence Tomography (OCT) [14]. These techniques allow to form a local detailed representation of the target.

External sensing refers to the use of external devices to track surgical instruments. On the basis of real-time sensing the six degrees-of-freedom (6 DoF) position and orientation of surgical tools used in intervention can be associated with preoperative or intraoperative information. Example of external trackers are Electro-Magnetic (EM) trackers such as the Aurora (Northern Digital Inc., Canada).

Table 2.1: Resume of C1 characteristics

Entry	Short Description
Intended Use	Novel advanced surgical assistance system for re-localisation of targets and automatic navigation towards them
Specification of the application – Use Case (scenario)	Simple, versatile and cost effective
General Requirements	Navigation system, OCT, EM, optical camera, Human-Machine graphical user-Interface (HMI)
Functional & Performance Requirements	Provide real-time navigation feedback for control (with an accuracy of 80–20 μm); Provide 2D/3D image for diagnosis(20–5 μm); Reduce overall pain level (maybe the dose of sedation can be reduced); Reduce operation time (50% - 80% of conventional colonoscopy system's insertion duration)
Usability Requirements	Setting up time should be no more than conventional colonoscopy; Provide GUI which can switch between automatic mode and manual mode; Data update rate should be maintained in both the automatic and manual mode

2.1 Intended Use

The primary functions of the ATLAS colonoscope system are the following:

- Ability to accurately detect the position of a target inside the colon (e.g.: situ with multiple polyps).
- Ability to automatically navigate towards the previously identified target after endoscopic extraction (needed in case of "en bloc" resection)
- Reduced friction between endoscope and colon wall thanks to system position awareness.

2.2 Specification of the application – Use Case

- The size of the designed colonoscope should not increase after modifications based on existing prototypes.
- The modification of colonoscopy should be simple in design, versatile and cost effective.
- The proposed device should be easily integrated with existing software and hardware.
- The modifications should not add extra complexity to the system hardware and software.

2.3 General Requirements

In this project, we propose a colonoscopic system that could allow autonomous navigation of the endoscope towards a previously-identified (and visited) region. The general requirement for the proposed work would be as follows:

1. Navigation system: The autonomous navigation techniques would be implemented through imitation learning-based techniques wherein the path followed by the surgeon previously would be used as the reference for path-planning.

Since the system is autonomous, an external robotic controller (Robotic arm or joystick) would be employed to push/pull the colonoscope.

2. Additional sensors can be incorporated in the endoscope:
   a) OCT: Reconstructing the colon in real-time
   b) EM: to get the tip position of the endoscope tip
   c) Optical camera: to reidentify the extracted polyp
3. HMI: to provide advanced visualization, haptic feedback and warning for safety issues. The surgeon can take over the control to manual mode by interacting with the HMI.

Quantitative description of specification is given in Table 2.2.

Table 2.2: System specifications

Insertion Tube	Tube diameter	13.2 mm
	Channel diameter	3.2 mm
	Total length	1816 mm
	Working Length	1500 mm
Optical System	Angle of View	140 °
	Focal range	4-100 mm
Bending Section	Angular Range	up-down 180 °
		right-left 275 °
Navigation	External Motor/robot	No info yet
	Software	GPU
OCT	Resolution	20-5 μ m
	Depth	50 mm
EM	Measurement rate	40Hz
	Positional accuracy	0.80 mm
	Orientation accuracy	0.70 °
HMI	Visualisation	Screen
	Haptic feedback	Haptic sensors

2.4 Functional & Performance Requirements

Functional requirements

The proposed colonoscopy system shall provide accurate navigation feedback for the control system of actuated colonscope, and, at the same time, shall provide 2D and 3D images with high resolution (20–5 micrometers), thanks to the combination of OCT, camera images and EM sensors. The control system is able to realize basic stabilization and scanning tasks with automatic guidance, which can reduce labour and fatigue of physicians, and release their tension in the operating room. In the meantime, it should provide a feedback about the distance (with an accuracy of 80–20 micrometers) between scanning center and lumen contour. Automatic endoscope centralization will also be realized, thus requiring fewer operators in one surgery, since the system will be operated by a single surgeon. Efficiency will increase compared with conventional colonoscopy, since it can only provide surface information.

Performance requirements

The main performance measure index to evaluate the effectiveness of the proposed robotic platform is the time taken to reach the target and the accuracy of target re-identification. Compared with the current standard of ESD in Western countries, the proposed system should shorten the duration of the second insertion (50% - 80% of conventional colonoscopy system's insertion time) in technically difficult cases, and outperform human surgeons in target re-identification.

Given the fact that the proposed system is able to reconstruct the 3D map of the traversed lumen, the navigation module can be trained so that the robot can adapt to the deformable colon structure; thus limiting the interaction forces between the colonoscope and colon.

2.5 Usability Requirements

The main usability requirements in the proposed system, which are crucial to achieve our purpose and provide the maximum comfort for the endoscopists are:

- The setting up time of proposed system should be no more than conventional conventional colonoscopy system.
- It should provide a GUI giving the endoscopist the opportunity to switch between automatic mode and manual mode and allow to display multiple information, briefly summarized in the next points.
- Compared with the conventional colonoscopy system, the depth information of lumen tissue will be acquired together with the surface information and displayed.
- Compared with conventional colonoscopy, higher resolution images of the lumen will be available for the clinician, thanks to the the fusion of white light camera data and OCT image. 2D images or 3D visualisation of the lumen on a 2D screen will be displayed interchangeably, according to the preference of the endoscopist.
- Real-time relative distance between probe and lumen contour (update rate can reach at least 100 Hz) will be showed.
- An historical trajectory could be also be provided, which can give more intuitive sense to the surgical operator.

3 C2 – Ureteroscopy

Ureteroscopy is a procedure that consists of the exploration of the upper urinary tract. Ureteroscopy is executed to diagnose and treat different conditions such as kidney stones or urothelial carcinoma of the upper urinary tract.

Urolithiasis or kidney stones disease is the formation in the urinary tract of crystalline aggregates of one or more components, most commonly calcium oxalate, uric acid, struvite or cystine. Urinary calculi may occur anywhere in the urinary tract, but they are more common to in the kidneys. In the case of cancer, tumors can be found at any point in the renal pelvis, renal calyces, and ureters. The most common are the ones that can be found in the renal pelvis and renal calyces being present in about 4-15% of the cases [18].

This procedure involves the passage of a ureteroscope through the urethra and bladder, and up the ureter to the point where the stone is located. The total travelling distance from the ureter orifice to the kidney stone ranges from 28 cm to 34 cm and the diameter of the ureter is only 5 mm in the pelvis [12]. The procedure starts with a cystoscopy. Cystoscopies allow to find the location of the ureteral orifices. The procedure may start with a first-look semi-rigid ureteroscopy in order to choose the most appropriate ureteral access sheath (UAS) size [19]. This is of great importance as UAS makes easier the multiple passages of the instrument during the removal of the stone fragments. Furthermore, it also helps in decreasing the internal pressure by facilitating the outflow of fluids [8]. Then, a guidewire is inserted and placed into the renal cavities to ensure access to the collecting system and facilitating the insertion of a stent used in case of collecting system injuries, such as perforation or excessive bleeding.

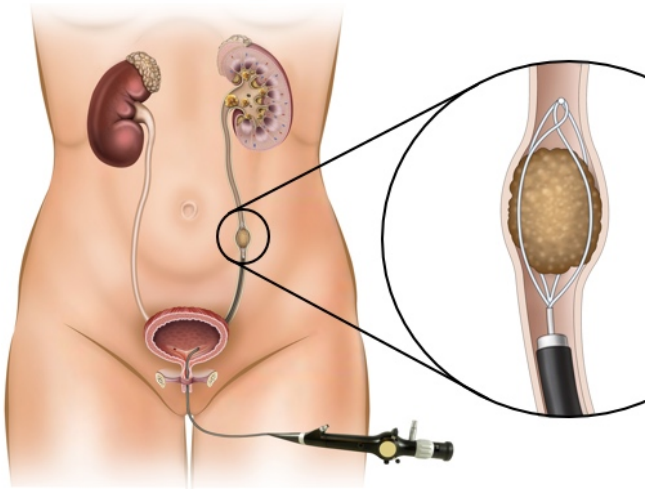

Figure 3.1: Ureteroscopy procedure and kidney stone removal. Image from https://brisbaneurologyclinic.com.au/procedures-we-perform/ureteroscopy/

Once the endoscope is inside the kidney, the exploration of the renal pelvis is carried out in order to identify all stones. The exploration is performed by first analysing the upper calices, followed by the middle ones, and finishing with the lower calices. Endoscope navigation takes place under fluoroscopic images and images recorded from the camera at the tip of the ureteroscope. This technique has several disadvantages. First, clinicians have to correlate the 2D image with the 3D map of the patient's anatomy in their mind. Second, the use of fluoroscopy exposes both patients and clinicians to ionizing radiation. Finally, the injection of nephrotoxic contrast agent is required to visualize the patient's anatomy from fluoroscopic images. To reduce the harmful effect from fluoroscopy, we intend to develop a new sensing technique that allows us to track the position and reconstruct the 3D shape of the endoscope during the procedure.

When the stones are identified, different strategies can be adopted. If the stones or fragments are small enough, they can be retrieved using a nitinol stone retrieval basket passed through the endoscope working channel. In order to avoid

urethral avulsion, stone retrieval with baskets needs to be endoscopically guided as depicted in Figure 3.1; this means that the stone and basket have to be kept under direct vision as they are removed. If the stones are larger than the diameter of the ureter, they must be shattered on-site into smaller pieces and removed. The fragmentation of the stones is commonly done by using a laser fiber source, usually a Ho:YAG pulsed laser (2100 nm). For the ablation of the tumors on upper tract carcinoma, several techniques have been described; including the use of the resectoscope, cup biopsy and Nd:YAG laser [18]. Although for these cases, the dusted tumor tissue is not retrieved, water irrigation is highly recommended in order to decrease the risk of tract seeding [13].

Finally, once the stones have been removed, or the tumor has been ablated a careful exploration of the ureter needs to be carried out to retrieve the scope and the UAS as well as to detect possible lesions that may have occurred during the procedure [32]. In cases in which injuries during the ureteroscopy are detected, or in cases were ureteral stricture or other anatomical impediments to stone fragment clearance are identified, guidelines recommend the placement of an ureteral stent.

Currently, there are two main types of endoscopic systems used in ureteroscopy: the fiberoptic ureteroscopy and the digital ureteroscopy. They differ by the way in which the light and the images are transmitted. The insertion of the endoscope is directly handled by the clinicians. The tip bending is normally controlled by a knob on the handle and only provide bending in one plane. In order to reach and search for kidney stones or tumors, which lie after tortuous paths, the instrument tip has to be steerable and with high flexibility. Traditional ureteroscope, *e.g.* Olympus URF-V, provides one steerable segment with 1 degree of freedom. The widest part of the shaft diameter is 9.9Fr and its total working distance is 670 mm. See Table 3.2 for the full specifications. To achieve the 3D movement, the rotation of the tip is coupled with the rotation of the endoscope's shaft. In this work, we propose an additional system to motorize the commercial endoscope to give clinicians better control on the movement.

The introduction of surgical intraluminal procedures (e.g. Ureteroscopy) has offered, so far, several benefits to the patients. Reduced blood loss, lower infection's risk, diminished scaring impact and quicker recovery time are among the most valuable ones. However, the practical application of these improvements has imposed high mental and physical stress on the clinicians [20] which may lead to errors and consequent complications.

In [23] a review of the most common intra-operative complications is presented. In this study, avulsion, major and minor perforation, mucosal abrasion and stricture are considered, with minor perforation appearing in more cases with an average of 1.99% of the analysed procedures, followed by stricture (0.58%). Major perforations that create complications appear with a lower probability (0.06% of the cases).

The solution we propose, to deal with the hitherto mentioned challenges, consists of building a supportive automatic system on top of a commercial ureteroscope. We are primarily addressing three problems: (i) Orientation of the ureteroscope: important during a ureteroscopy, when the precise operation and identification of the target are essential, [12]; (ii) Minor perforations of the ureter: ranked as a second high injury grade of the ureteral wall after ureteral avulsion. It happens in 3.3% of patients when ureteral access sheath is used, [31]; (iii) Guidance of the surgery: current endoscopic devices miss an intuitive guidance interface, which could help the surgeons making the procedure easier to perform. We propose to integrate additional sensors such as EM tracker and Fiber Bragg Grating (FBG) sensors into the existing design of the ureteroscope in order to achieve our goals. Alongside this, our proposed system will consist of an intuitive HMI design to reduce surgeons' cognitive and physical load.

The structure of this section is presented in Table 3.1.

Table 3.1: Resume of C2 characteristics.

Entry	Short Description
Intended Use	The proposed system is intented to be used as a novel advanced surgical assistance system.
Specification of the application – Use Case (scenario)	Our proposed solution provides the user with an advanced aid system control, user interface, automated tracking, and guidance assistance.
General Requirements	Based on commercial ureterescope design, the proposed system should be able to prevent perforation and provide visualization of the anatomy model and ureteroscope posture during the surgery with the new sensing method.
Usability Requirements	User-centered HMI endowed with an intuitive and task oriented GUI, an ergonomic user controller, and a multilevel surgical assistance system.

3.1 Intended Use

The principal functionalities of the ATLAS ureteroscope system are:

- Precise automated real-time tracking of the endoscope
- Ability to automatically detect and localize the urinary calculi
- Ability to automatically recognise the current state of the surgery
- A teleoperated system with an intuitive HMI to guide the surgeons including an ergonomic controller for fine control

3.2 Specification of the application – Use Case

The goal of this project is to develop an autonomous ureteroscope that assists the surgeons with various degrees of autonomy. Our proposed solution consists of the following four use cases with increasing degree of autonomy:

Case 1: Assisted Control Our proposed solution consists of an ergonomic controller that provides the user with an easy and intuitive low-level control mechanism through a haptic phantom.

Case 2: Advanced Teleoperation One of the important functionality of our solution is the development of an endoscope that could be operated remotely. The remote platform will be provided for the user consisting of an intuitive ergonomic controller introduced above with haptic feedback and a user interface comprising of visual feedback which is obtained from the sensing modalities (e.g., endoscopic camera, EM trackers, and FBG sensors).

Case 3: Automated Tracking The teleoperation system enables the user with the ability to view and track the progress of the endoscope in real-time which will be achieved autonomously by abstracting information from the sensing modalities (e.g., EM trackers and FBG sensors) and the low-level control of the endoscope: propulsion, rotations, *etc.*.

Case 4: Advanced Guidance The teleoperation system will be enhanced further to provide operators with automated support and guidance. This will be accomplished by automated surgical phase detection and calculi segmentation.

3.3 General Requirements

In this project, we plan to build a supportive automatic system on top of a commercial ureteroscope which aims to solve the aforementioned problems. The requirements of the envisioned system are the following:

- The ureteroscope, equipped with embedded EM and FBG sensors, should comply to all the existing specifications and dimensions of an existing ureteroscope. Table 3.2 shows such specifications using the Olympus URF-V as reference.
- An additional actuation mechanism should drive motion of the ureteroscope during the surgery.
- EM sensor and FBG sensors will be integrated into the device to measure the pose and shape of the ureterocscope during the surgery.

- The system will provide surgeons a more user-friendly HMI to control the ureteroscope. Visualization of pose and shape of the ureteroscope will be displayed as a guidance of the surgery throughout the entire procedure.

Table 3.2: Olympus URF-V uretroscope specifications

Optical System	FOV	90 degree
	Direction of View	one way
	Depth of View	2 - 50 mm
Insertion Tube	Shaft Size	9.9 Fr
	Shaft Lumen Size	3.6 Fr
	Tip Size	8.5 Fr
	Working Length	670mm
Bending Section	Angular Range	up 180 degree down 275 degree

3.4 Functional & Performance Requirements

The new sensing method has to qualify the following requirements:

- To give real-time visualization of both position and the shape of endoscope during procedure.
- Provide uniform accuracy throughout the whole tracking volume (accuracy: 3mm or less).
- To ensure robustness of the tracking system (e.g. the influence of metallic or ferromagnetic objects in the operating room).
- To reduce the fluoroscopic frame rate used in the procedure to 1-5 frames per second.
- The embedded sensors need to be small size, lightweight and highly elastic, in order to allow for easy integration and to minimize the increase of the overall stiffness of the endoscope (FBGs are often assumed to have negligible stiffness).
- Easy calibration process (it should require less than 5 minutes to perform).

The plug-in actuation system (that will actuate the endoscope) requires the following characteristics:

- Lightweight (less than 500 gram).
- Compatible with a commercial manually-steerable endoscope.
- Provide fine movement control for clinicians.

3.5 Usability Requirements

Over the years, continuous development of the intraluminal procedures has resulted in noticeable benefits for the patients; however, these improvements imposed high mental and physical stress to the clinicians, [20]. Manoeuvring a standard endoscope often leads endoscopists to experience wrist tendons inflammations, back pain, and neck discomfort, [34]. In addition, the limited intuitiveness of the controller, and the lack of guidance provided by the Graphical User Interface (GUI), make procedures like ureteroscopy challenging to perform and to master.

In response to these issues, the proposed system aims at increasing both the ease of use, and the ease of learning standard uretoscopic procedures. This goal will be achieved by developing a more user-friendly and user-centered system, with respect to the standard one. The new design, therefore, will aim at addressing the following usability requirements, which are crucial for the specific application.

- A **user-centered design** developed by interviewing the final users (*i.e.* urologist) and accurately analysing the surgical procedure. The final goal is to assess all the usability specification, and all the useful information to

transmit to the doctors during the surgery. These feedbacks will be later conveyed to the user by exploiting virtual reality, haptic feedbacks, on-line maps of the catheter position, etc.

- An **ergonomic** electromechanical interface allowing a commercial ureteroscope to be paired, hence manually controlled through a haptic phantom. The latter requires limited force to be manoeuvred, and a more natural wrist pose with respect to the standard device controllers. These features will intrinsically increase the clinician's safety throughout the whole procedure.
- An **intuitive and task-oriented GUI** supporting the surgeons with specific tools (*e.g.* guidance, suggestions, directions *etc.*) depending on the phase and action in execution. In this way, the information provided is maximized for each phase of the procedure, minimizing the surgeon's cognitive effort.
- A **multilevel control autonomy** system and HMI providing different levels of assistance and control to the clinician.

4 C3 – Endovascular Catheterization

Clinical Problem

A Chronic Total Occlusion (CTO) is a type of arterial blockage affecting the coronary arteries of the heart; the term "chronic" implying that the occlusion has persisted for more than three months. Recent studies found that CTOs are found in 16-20% of all patients with coronary heart disease undergoing non-emergency angiography [4] [21]. Fefer et al. (2012) [10] found that of a cohort of 1,697 patients with identified CTOs, 30% were treated with Percutaneous coronary intervention (PCI). However, only 10% of these patients underwent an attempt to treat their CTOs, with a success rate of 70%. In other words, only 7% of CTO patients were successfully treated by PCI. One study bucks this trend, however: Suzuki et al. [30] published results from the Japanese CTO-PCI registry showing overall success rates as high as 89.9%. This was achieved by admitting only physicians who performed at least 50 CTOs-PCIs per year and more than 300 procedures overall to the database. This remarkable discrepancy suggests that with sufficient operator experience and skill, CTOs can not only be treated successfully via PCI, but also with a high rate of success. The need for tools that can mitigate the skill and experience requirements for percutaneous treatment of CTOs is thereby highlighted.

According to Reifart [22]:

> *"The most important prerequisite is operator and team experience in CTO procedures. The operator should be skilful, trained specifically in CTO intervention, be patient, persistent and yet cautious. Every operator should select patients according to their level of expertise or seek for expert backup or refer those beyond their reach to CTO masters."*

Anatomy of a CTO-PCI Procedure

Brilakis et al. [6] published a detailed, algorithmic approach to the percutaneous recanalization of coronary CTOs. The paper describes four angiographic characteristics as the starting point of its algorithm:

1. the location and shape of the proximal (upstream) cap of the lesion, as determined by angiography and intravascular ultrasound (IVUS);
2. the length of the lesion, determined by dual injection angiography;
3. the size and condition of the occluded vessel; and
4. the size and suitability of collateral vessels for retrograde techniques.

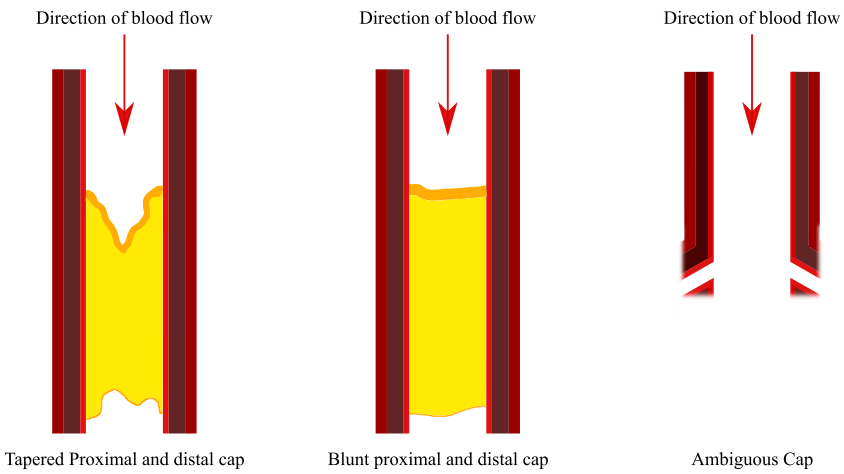

Figure 4.1: Proximal cap shapes.

It is recommended that lesions shorter than 20mm be primarily approached using an antegrade wire escalation; in other words the clinician should attempt to cross the CTO directly by pushing through it with a guidewire (see Figure 4.2). This is known as a wire escalation strategy. It should be noted that this has the highest chance of success if the occlusion has a tapered proximal cap vs. a blunt or ambiguous cap (see Figure 4.1). Lesions greater than 20mm in length where the proximal cap and distal target are clearly defined are candidates for primary dissection and re-entry, where a guidewire is passed between the tunica media and the tunica intima of the vessel in the so-called subintimal space (see Figure 4.3). Other lesions, such as those with ambiguous caps and poor distal target sites may be preferably approached in retrograde.

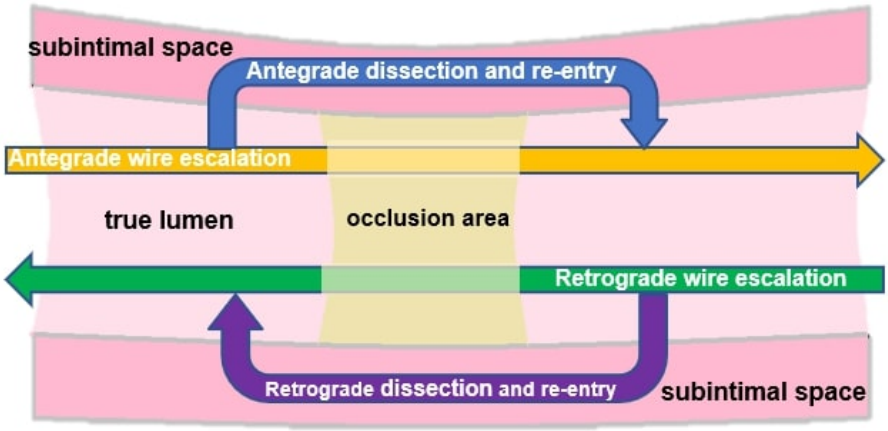

Figure 4.2: Possible approaches to cross a CTO involve either channelling through the occlusion or bypassing it through the subintimal space of the arteries.

In wire escalation strategies, the lesion is first gently probed with a low-gram-force, polymer-jacketed wire with slowly increasing force. In case buckling is observed on the fluoroscopic image, an over-the-wire catheter is forwarded to improve the wire's buckling resistance. If the wire is deemed insufficient, it is replaced with a more rigid wire.

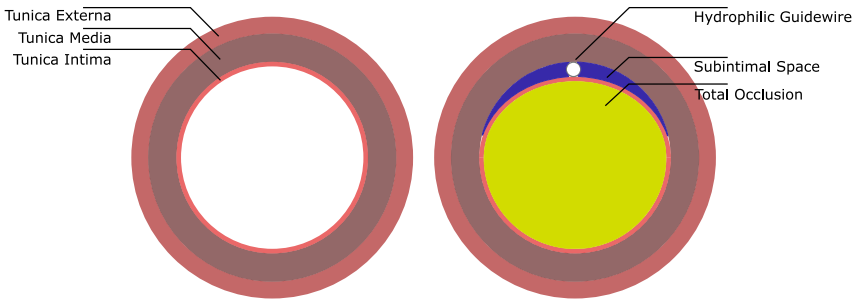

Figure 4.3: Sub-intimal guidewire insertion. *Left*: Primary layers of an artery. *Right*: The subintimal space with a guidewire (*e.g.* during dissection and re-entry).

If the lesion is still not crossed, the clinician should convert to a dissection and re-entry technique. This strategy involves the clinician directing the wire between the layers of the arterial wall, rather than through the mass of the occlusion itself. Once past the occlusion, the wire is guided back into the lumen of the vessel. This can be done in two ways; in the wire based re-entry method a catheter is placed over the wire in the subintimal space; the wire is then replaced with a high-gram-force re-entry wire that can punch through the tunica intima and into the distal true lumen. The device-based method involves a specialised catheter [29] (Stingray LP ™, Boston Scientific, Marlborough, MA, USA) with a flat balloon; upon inflation the balloon orients itself parallel to the layers of the vessel, aligning its access ports with the true lumen of the vessel. A re-entry catheter is then used to gain access to the distal true lumen.

Once the occlusion has been crossed, a balloon angioplasty is performed in order to dilate the vessel and allow blood flow to resume; and to keep a patent lumen, a stent is usually placed in the affected vessel.

Table 4.1: Summary of C3 characteristics.

Entry	Short Description
Intended Use	Localisation, and disintegration or bypassing of occlusion
Specification of the application – Use Case (scenario)	Dexterous, easy to use and fast to deploy system
General Requirements	Assistance and compatibility
Functional & Performance Requirements	Stable path planning and real-time Three Dimensional (3D) reconstruction from CT angiogram data and IVUS images. Deployment module to contain at least 2 internal lumens for carrying IVUS probes, magnetic catheters and guidewires. This module should be anchored at the aortic valve providing directed exits towards the two coronary arteries. The dimensions of the components should be within anatomically allowed limits.
Usability Requirements	A 3-axis joystick to maneuver the deployment module, the catheters and the guidewires. The manipulation of the different modules is guided through the visualization of a 3D reconstruction of the lumen, viewed on a Two Dimensional (2D) screen available to the surgeon.

4.1 Intended Use

This ATLAS CTO system should be able to:

- localize the occlusion;
- enter, push, and exit the vascular lumen stably and safely;
- avoid any perforation of the artery walls;
- either disintegrate the occlusion or bypass it through the subintimal space of the artery walls; and
- validate the proper placement of the stent.

4.2 Specification of the application – Use Case

- The installation and setup should be intuitive and simple.
- The entire system should be operable by left-handed and right-handed operators.
- The deployment module should be suitable to be inserted through both, left and right, femoral arteries.
- The system should have the ability to reach both sides of the occlusion.

4.3 General Requirements

- The system is intended to assist surgeons by imparting some autonomy to the procedure, while still granting them full control of the procedure.
- The system should be able to semi-autonomously, upon the surgeon's command, manipulate the deployment module till the aortic valve and anchor it there.
- The entire system should be compatible with existing guidewires and catheters.
- The entire system should be compatible with currently adopted operating room equipment and imaging modalities.

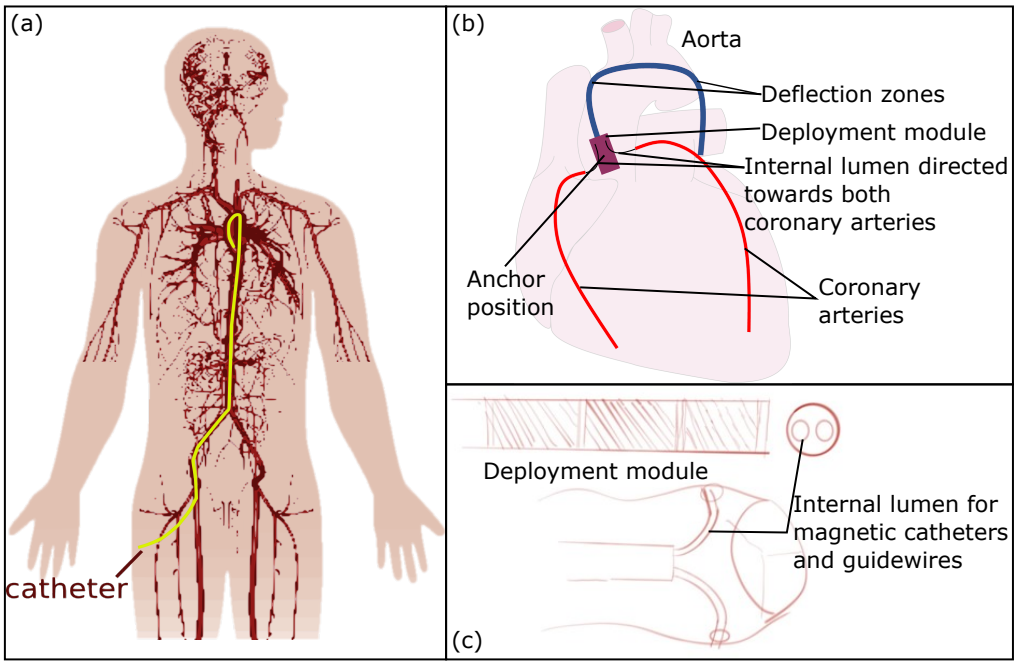

Figure 4.4: Phases of the catheterization procedure. (a) The catheterization procedure starts entering from the femoral arteries. (b) A schematic of the deployment module anchored in the aorta. (c) A preliminary design of the deployment module showing the narrow lumen for the deployment of catheters, guidewires and IVUS probe (not to scale).

4.4 Functional & Performance Requirements

- The analysis of pre-operative CT angiogram data should be carried out for:
  - path planning,
  - anchor position determination for the deployment module, and
  - determination of the angles at which the catheters and guidewires should be deployed.
- Moreover, pre-operative 3D segmentation should be performed in order to determine stable path planning and to identify ideal deflection zones.
- The diameter of the deployment module should be at most 7 mm.
- The deployment module should carry an EM sensor for accurate (within 1 mm) position sensing.
- The deployment module should have a minimum of two internal lumens, of at least 1.5 mm diameter each, providing curved exits (one for each coronary artery).
- The diameters of magnetic guidewires/catheters to be deployed should correspond to the current conventions.
- The guidewires and catheters should have magnetic steering capability.
- Real-time 3D vessel reconstruction using IVUS.
- The validation of stent placement should be done objectively using IVUS.
- Occlusion sensing accuracy should be within 1 mm.
- Positioning error of flexible catheter/guidewires actuated by magnets/artificial muscles should be within 1 mm.

A schematic of a potential design of our system is shown in Figure 4.4.

4.5 Usability Requirements

- The setup time should be short, approximately 10 minutes.
- the GUI should provide visualization in 3D (lumen and probe) on a 2D screen. Additionally, the user should be able to rotate the 3D view without limitations.

- Guidance of the catheter should be as intuitive as possible by providing a desired reference path onto the 3D model.
- A GUI should provide manual and semi-autonomous manipulation options for the deployment module.
- For manual manipulation, the foreseen solution is a joystick-like interface that commands both the deployment module as well asd the deployed catheters and guidewires.

5 Conclusion

This deliverable reports on the first steps by the ESRs to design an innovative integrated system for autonomous navigation through the colon, the ureter or the vasculature. For each situation the workflow, the intended use and the specification and requirements are listed. Aside from working in teams, ESRs were also encouraged warmly to get to know the contributions of the other teams. It is expected that this overview will allow faster progress in the future where through cross-fertilization advanced features can travel from one scenario to another. This deliverable will form the base of further integration efforts that are planned along the entire duration of the project.

The ATLAS project

last modified: April 19, 2020

ATLAS-D10.2-2.0.0

Horizon 2020

Bibliography

[1] Emmanuel Akintoye et al. "Colorectal endoscopic submucosal dissection: a systematic review and meta-analysis". In: *Endoscopy international open* 4.10 (2016), E1030–E1044.

[2] Alberto Arezzo et al. "Systematic review and meta-analysis of endoscopic submucosal dissection vs endoscopic mucosal resection for colorectal lesions". In: *United European gastroenterology journal* 4.1 (2016), pp. 18–29.

[3] DE Azagury et al. "Real-time computed tomography-based augmented reality for natural orifice transluminal endoscopic surgery navigation". In: *British journal of surgery* 99.9 (2012), pp. 1246–1253.

[4] Lorenzo Azzalini et al. "Epidemiology, Management Strategies, and Outcomes of Patients With Chronic Total Coronary Occlusion". In: *American Journal of Cardiology* 118.8 (Oct. 2016), pp. 1128–1135. ISSN: 18791913. DOI: 10.1016/j.amjcard.2016.07.023.

[5] Matthias Baumhauer et al. "Navigation in endoscopic soft tissue surgery: perspectives and limitations". In: *Journal of endourology* 22.4 (2008), pp. 751–766.

[6] Emmanouil S. Brilakis et al. "A percutaneous treatment algorithm for crossing coronary chronic total occlusions". In: *JACC: Cardiovascular Interventions* 5.4 (2012), pp. 367–379. ISSN: 18767605. DOI: 10.1016/j.jcin.2012.02.006.

[7] *Council Directive 93/42/EEC of 14 June 1993 concerning medical devices and amendmens*. https://eur-lex.europa.eu/legal-content/EN/TXT/?uri=CELEX:01993L0042-20071011. 2007.

[8] Steeve Doizi and Olivier Traxer. "Flexible ureteroscopy: technique, tips and tricks". In: *Urolithiasis* 46.1 (Feb. 2018), pp. 47–58. ISSN: 2194-7236. DOI: 10.1007/s00240-017-1030-x. URL: https://doi.org/10.1007/s00240-017-1030-x.

[9] Audrius Dulskas, Žygimantas Kuliešius, and Narimantas E Samalavičius. "Laparoscopic colorectal surgery for colorectal polyps: experience of ten years". In: *Acta medica Lituanica* 24.1 (2017), p. 18.

[10] Paul Fefer et al. "Current perspectives on coronary chronic total occlusions: The Canadian multicenter chronic total occlusions registry". In: *Journal of the American College of Cardiology* 59.11 (Mar. 2012), pp. 991–997. ISSN: 15583597. DOI: 10.1016/j.jacc.2011.12.007.

[11] Lorenzo Fuccio et al. "Clinical outcomes after endoscopic submucosal dissection for colorectal neoplasia: a systematic review and meta-analysis". In: *Gastrointestinal endoscopy* 86.1 (2017), pp. 74–86.

[12] Guido Giusti et al. "Current Standard Technique for Modern Flexible Ureteroscopy: Tips and Tricks". In: *European Urology* 70.1 (2016), pp. 188–194. ISSN: 0302-2838. DOI: https://doi.org/10.1016/j.eururo.2016.03.035. URL: http://www.sciencedirect.com/science/article/pii/S0302283816300112.

[13] Mahesh C Goel, V Mahendra, and JG Roberts. "Percutaneous management of renal pelvic urothelial tumors: long-term followup". In: *The Journal of urology* 169.3 (2003), pp. 925–930.

[14] Michalina J Gora et al. "Endoscopic optical coherence tomography: technologies and clinical applications". In: *Biomedical optics express* 8.5 (2017), pp. 2405–2444.

[15] Yasuyuki Ichise et al. "Prospective randomized comparison of cold snare polypectomy and conventional polypectomy for small colorectal polyps". In: *Digestion* 84.1 (2011), pp. 78–81.

[16] Kesavan Kandiah, Sharmila Subramaniam, and Pradeep Bhandari. "Polypectomy and advanced endoscopic resection". In: *Frontline gastroenterology* 8.2 (2017), pp. 110–114.

[17] Sergey V Kantsevoy et al. "Endoscopic mucosal resection and endoscopic submucosal dissection". In: *Gastrointestinal endoscopy* 68.1 (2008), pp. 11–18.

[18] Kalyan C Latchamsetty and Christopher R Porter. "Treatment of upper tract urothelial carcinoma: a review of surgical and adjuvant therapy". In: *Reviews in urology* 8.2 (2006), p. 61.

[19] Manoj Monga. *Ureteroscopy: indications, instrumentation & technique*. Springer Science & Business Media, 2012.

[20] A Orekhov, Colette Abah, and Nabil Simaan. "Snake-like robots for minimally invasive, single-port, and intraluminal surgeries". In: *The Enciclopedia of Medical Robotics*. World Scientific, 2018, pp. 203–243.

[21] Truls Råmunddal et al. "Chronic total occlusions in Sweden - A report from the Swedish Coronary Angiography and Angioplasty Registry (SCAAR)". In: *PLoS ONE* 9.8 (Aug. 2014). ISSN: 19326203. DOI: 10.1371/journal.pone.0103850.

[22] Nicolaus Reifart. "Challenges in complicated coronary chronic total occlusion recanalisation". In: *Interventional Cardiology (London)* 8.2 (2013), pp. 107–111. ISSN: 17561485. DOI: 10.15420/icr.2013.8.2.107.

[23] Jean JMCH de la Rosette, Thomas Skrekas, and Joseph W Segura. "Handling and prevention of complications in stone basketing". In: *European urology* 50.5 (2006), pp. 991–999.

[24] Yutaka Saito, Amit Bhatt, and Takahisa Matsuda. "Colorectal endoscopic submucosal dissection and its journey to the West". In: *Gastrointestinal endoscopy* 86.1 (2017), pp. 90–92.

[25] Guh Jung Seo et al. "Recurrence after endoscopic piecemeal mucosal resection for large sessile colorectal polyps". In: *World journal of gastroenterology: WJG* 16.22 (2010), p. 2806.

[26] Myeongsook Seo et al. "Clinical outcomes of colorectal endoscopic submucosal dissection and risk factors associated with piecemeal resection". In: *The Turkish Journal of Gastroenterology* 29.4 (2018), p. 473.

[27] Myeongsook Seo et al. "Local recurrence and subsequent endoscopic treatment after endoscopic piecemeal mucosal resection with or without precutting in the colorectum". In: *Intestinal research* 15.4 (2017), p. 502.

[28] Rebecca L Siegel et al. "Colorectal cancer statistics, 2017". In: *CA: a cancer journal for clinicians* 67.3 (2017), pp. 177–193.

[29] *STINGRAY LP Coronary CTO Re-Entry System - Boston Scientific*. URL: https://www.bostonscientific.com/en-US/products/cto-systems/stingray-cto-balloon-catheter-and-guidewire.html (visited on 02/03/2020).

[30] Yoriyasu Suzuki et al. "Outcomes of Percutaneous Coronary Interventions for Chronic Total Occlusion Performed by Highly Experienced Japanese Specialists: The First Report From the Japanese CTO-PCI Expert Registry". In: *JACC: Cardiovascular Interventions* 10.21 (Nov. 2017), pp. 2144–2154. ISSN: 18767605. DOI: 10.1016/j.jcin.2017.06.024.

[31] Olivier Traxer and Alexandre Thomas. "Prospective Evaluation and Classification of Ureteral Wall Injuries Resulting from Insertion of a Ureteral Access Sheath During Retrograde Intrarenal Surgery". In: *Journal of Urology* 189.2 (2013), pp. 580–584. DOI: 10.1016/j.juro.2012.08.197. eprint: https://www.auajournals.org/doi/pdf/10.1016/j.juro.2012.08.197. URL: https://www.auajournals.org/doi/abs/10.1016/j.juro.2012.08.197.

[32] Olivier Traxer and Alexandre Thomas. "Prospective evaluation and classification of ureteral wall injuries resulting from insertion of a ureteral access sheath during retrograde intrarenal surgery". In: *The Journal of urology* 189.2 (2013), pp. 580–584.

[33] Guang Zhong Yang et al. "Medical robotics-Regulatory, ethical, and legal considerations for increasing levels of autonomy". English (US). In: *Science Robotics* 2.4 (Mar. 2017). ISSN: 2470-9476. DOI: 10.1126/scirobotics.aam8638.

[34] Diana Yung et al. "Musculoskeletal injuries in gastrointestinal endoscopists: a systematic review". In: *Expert Review of Gastroenterology & Hepatology* 11 (July 2017).